

Deciphering the Neural Signature of Conversion Blindness

TO THE EDITOR: Conversion disorder, formerly known as hysteria, is thought to symptomatically manifest in the sensory-motor domains as a result of emotional distress (1). The prevailing neurocircuitry models based on functional MRI (fMRI) studies of patients with conversion paralysis support this view by suggesting an association of frontolimbic hyperfunction and suppressed motor responses (2). Less is known, however, about the neural signature of visual conversion disorder. While two recent fMRI studies have documented altered, but not absent, visual cortex responses in patients with conversion blindness (3, 4), it remains unclear whether the neural processing of symptom-related cues is preserved.

We report here on a 25-year-old man who fulfilled DSM-IV criteria for visual conversion disorder after experiencing recurrent brief episodes of medically unexplained complete bilateral visual loss. These episodes had occurred since he was 17 years old when his close boyhood friend accidentally died from autoerotic asphyxiation. The current episode was preceded by overwhelming feelings of guilt and visual pseudo-hallucinations showing his deceased friend's face grimacing with agony. In an attempt to elucidate the underlying neurocircuitry using fMRI, we scanned the patient during the episode of conversion blindness and after spontaneous remission 5 days later, thus enabling intra-individual comparison of neural activity during symptomatic and asymptomatic states in the absence of pharmacotherapy.

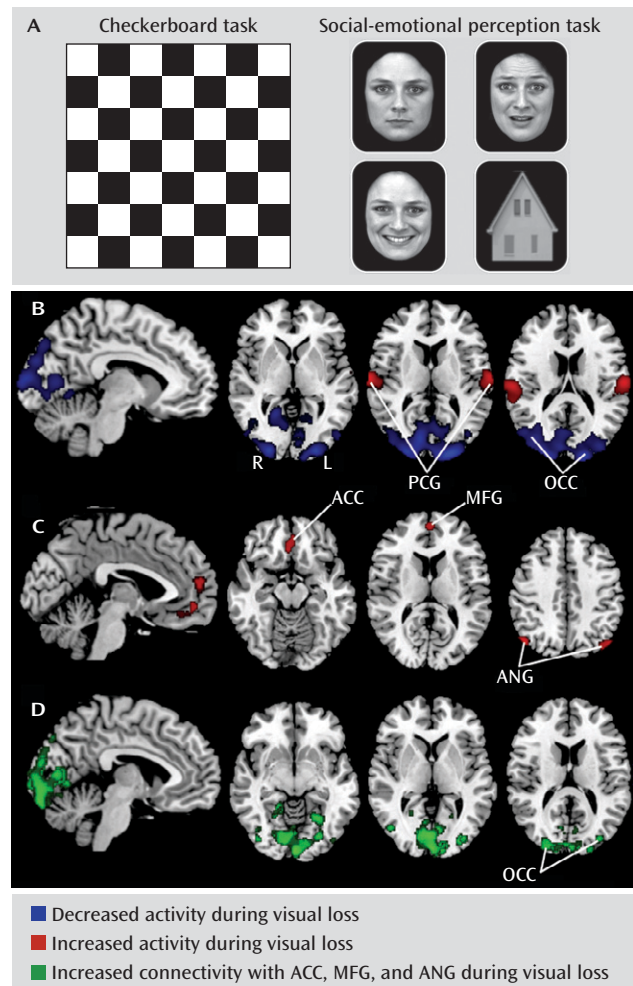
Our fMRI data analysis confirmed the presence of unaltered basic visual cortex responses to checkerboard stimulation (Figure 1A) during conversion blindness (3, 4). In contrast, analysis of higher-order visual responses to complex stimuli (a social-emotional perception task) revealed hypofunction in the occipital cortex and hyperfunction in the postcentral gyrus bilaterally and the right superior temporal gyrus (Figure 1B). The extraction of emotion-specific activity yielded increased responses in the angular gyrus bilaterally, the left medial frontal gyrus, and the left anterior cingulate cortex—regions implicated in a variety of brain functions including emotional regulation and moral reasoning (Figure 1C). A psychophysiological-interactions analysis revealed enhanced functional coupling of this network with down-regulated visual areas (Figure 1D).

Taken together, our findings may help extend current neurocircuitry models of functional conversion disorder by proposing a symptom-related functional association of overactivity in frontoparietal regions and suppressed responses in interconnected visual areas.

References

1. Reynolds EH: Hysteria, conversion and functional disorders: a neurological contribution to classification issues. *Br J Psychiatry* 2012; 201:253–254
2. Vuilleumier P: Hysterical conversion and brain function. *Prog Brain Res* 2005; 150:309–329
3. Werring DJ, Weston L, Bullmore ET, Plant GT, Ron MA: Functional magnetic resonance imaging of the cerebral response to visual

FIGURE 1. Visual Tasks and fMRI in a Study of Conversion Blindness^a



^a Panel A displays the functional MRI paradigms employed to probe basic and higher-order visual processing in a patient with conversion blindness. Panels B–D display the neural response and functional connectivity changes during presence relative to absence of conversion blindness. All results are family-wise error corrected at the cluster level ($p < 0.05$). OCC=occipital cortex; ACC=anterior cingulate cortex; MFG=medial frontal gyrus; ANG=angular gyrus; PCG=postcentral gyrus.

stimulation in medically unexplained visual loss. *Psychol Med* 2004; 34:583–589

4. Schoenfeld MA, Hassa T, Hopf JM, Eulitz C, Schmidt R: Neural correlates of hysterical blindness. *Cereb Cortex* 2011; 21: 2394–2398

BENJAMIN BECKER, Ph.D.
DIRK SCHEELE, M.Sc.
RAINALD MOESSNER, M.D.
WOLFGANG MAIER, M.D.
RENÉ HURLEMANN, M.D., Ph.D.

From the Department of Psychiatry, University of Bonn, Germany, and the German Center for Neurodegenerative Diseases (DZNE), Bonn.

The authors report no financial relationships with commercial interests.

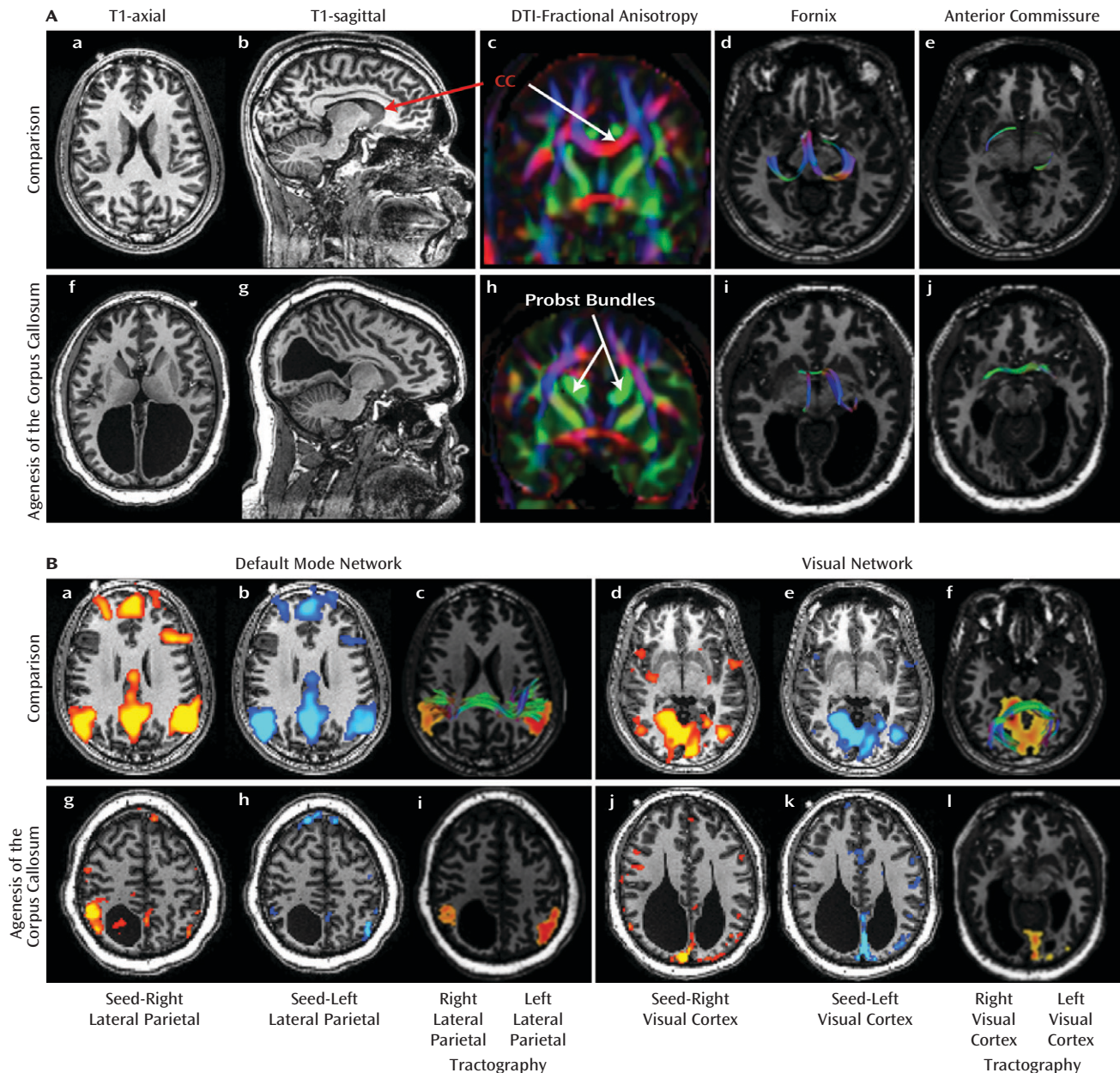
Dr. Hurlmann was supported by a German Research Foundation grant (HU-1302/2-2) and by a Starting Independent Researcher Grant (Neuromodulation of Emotion) jointly provided by the Ministry of Innovation, Science, Research, and Technology of the German State of North Rhine-Westphalia and the University of Bonn, Germany.

This letter (doi: 10.1176/appi.ajp.2012.12070905) was accepted for publication in November 2012.

Altered Functional and Structural Connectivity in a Schizophrenia Patient With Complete Agenesis of the Corpus Callosum

TO THE EDITOR: We incidentally detected complete agenesis of the corpus callosum (1, 2) in a 34-year-old married African American man with schizophrenia who was referred for a resting-state functional MRI (fMRI) and diffusion tensor imaging (DTI) research study. The patient had a 5-year history of

FIGURE 1. Brain Imaging From a Study of Complete Agenesis of the Corpus Callosum^a



^a Panel A depicts the anatomical and DTI images from a healthy comparison subject (a–e) and the patient with agenesis of the corpus callosum (CC) (f–j). The corpus callosum is completely absent in the patient, leading to enlarged ventricles (colpocephaly) and prominent Probst bundles (green in panel h). In contrast, the fornix (d, i) is preserved, and the anterior commissure is prominent (e, j). Panel B depicts resting blood-oxygen-level-dependent images (a, b, d, e, g, h, j, k) and DTI tractography images (c, f, i, l) from a healthy comparison subject (a–f) and the patient with agenesis of the corpus callosum (g–l). Regions of interest were placed in the left and right lateral parietal and visual cortex to study the default mode (a, b) and visual networks (d, e). Relative to the healthy comparison subject, default mode network (g, h) and visual network (g, h) connectivity were markedly reduced in the patient ($3 < z < 7$). The callosal fibers connecting the parietal (c) and visual (f) cortex region of interest in the healthy comparison subject are missing in the patient with agenesis of the corpus callosum (i, l).